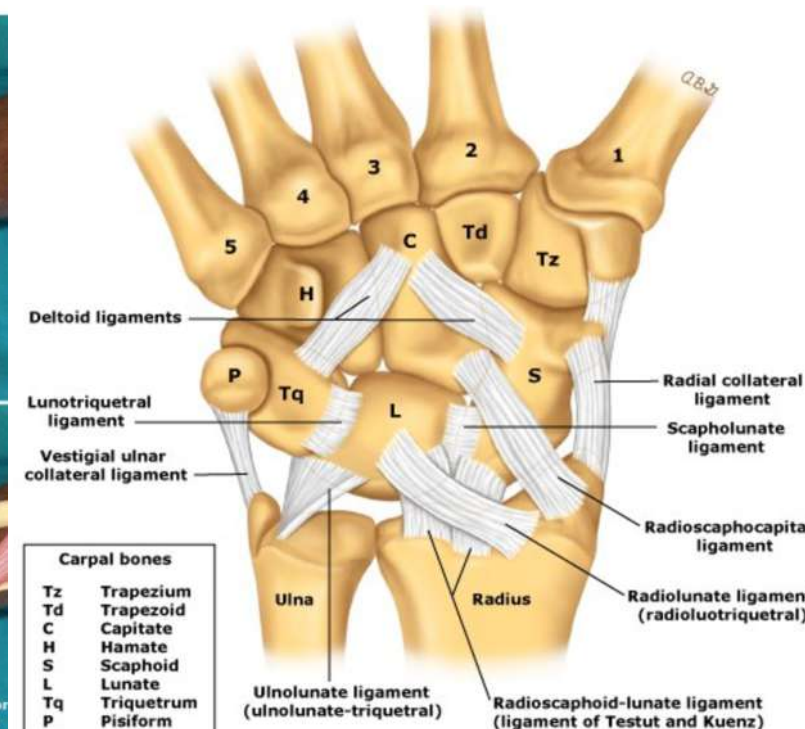
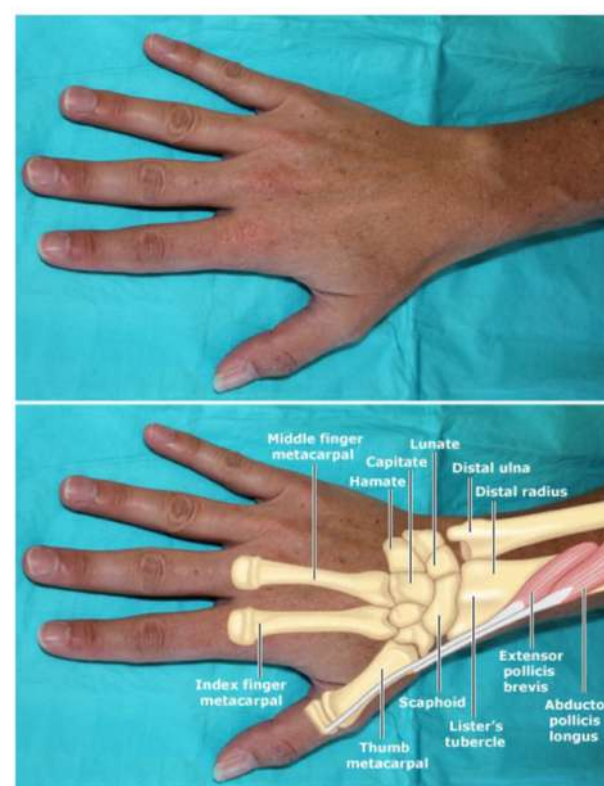
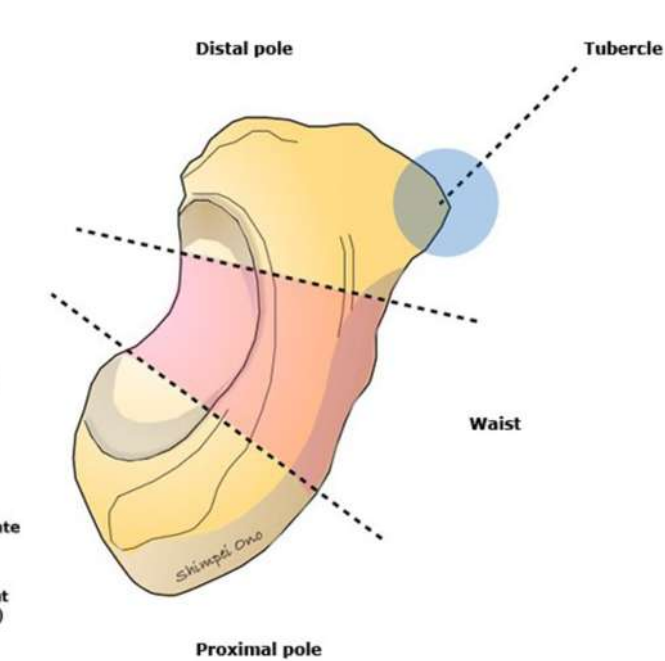


Dorsal wrist external appearance

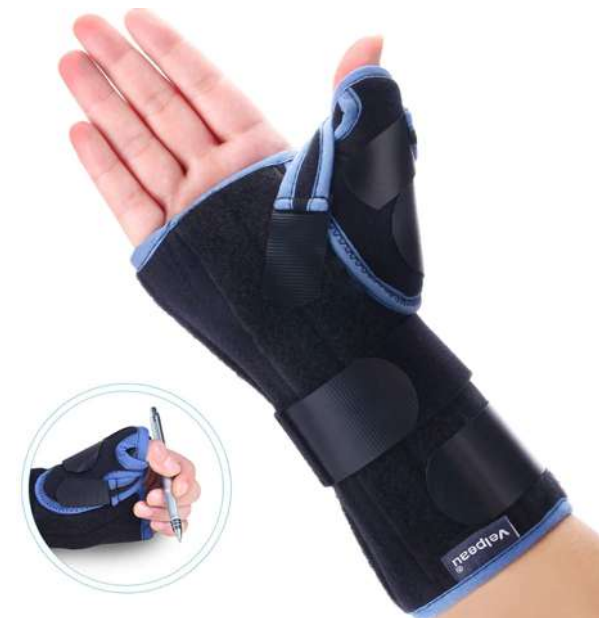

The figure shows the volar surface of the wrist.

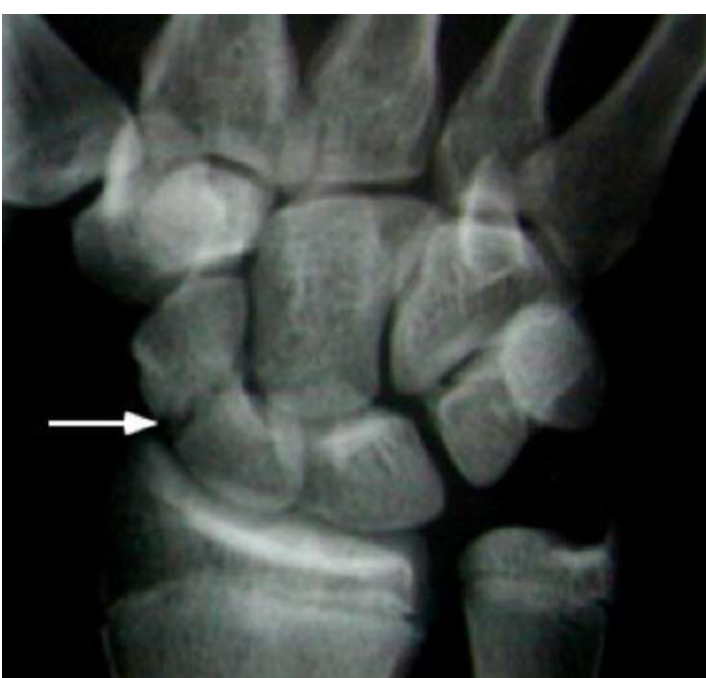Anatomy of hand fractures - Scaphoid



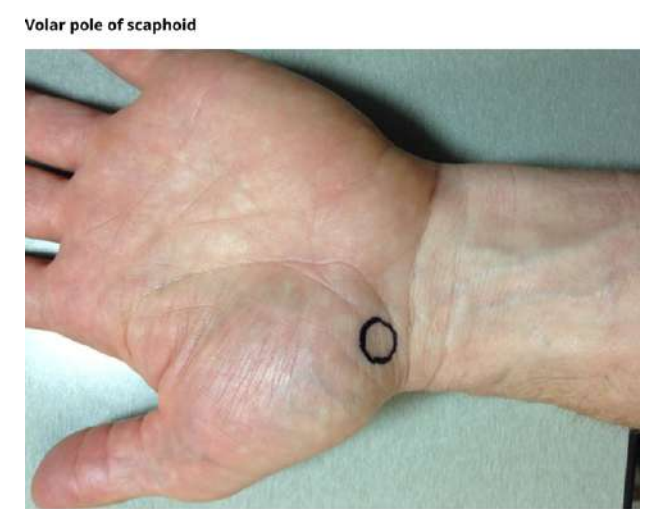
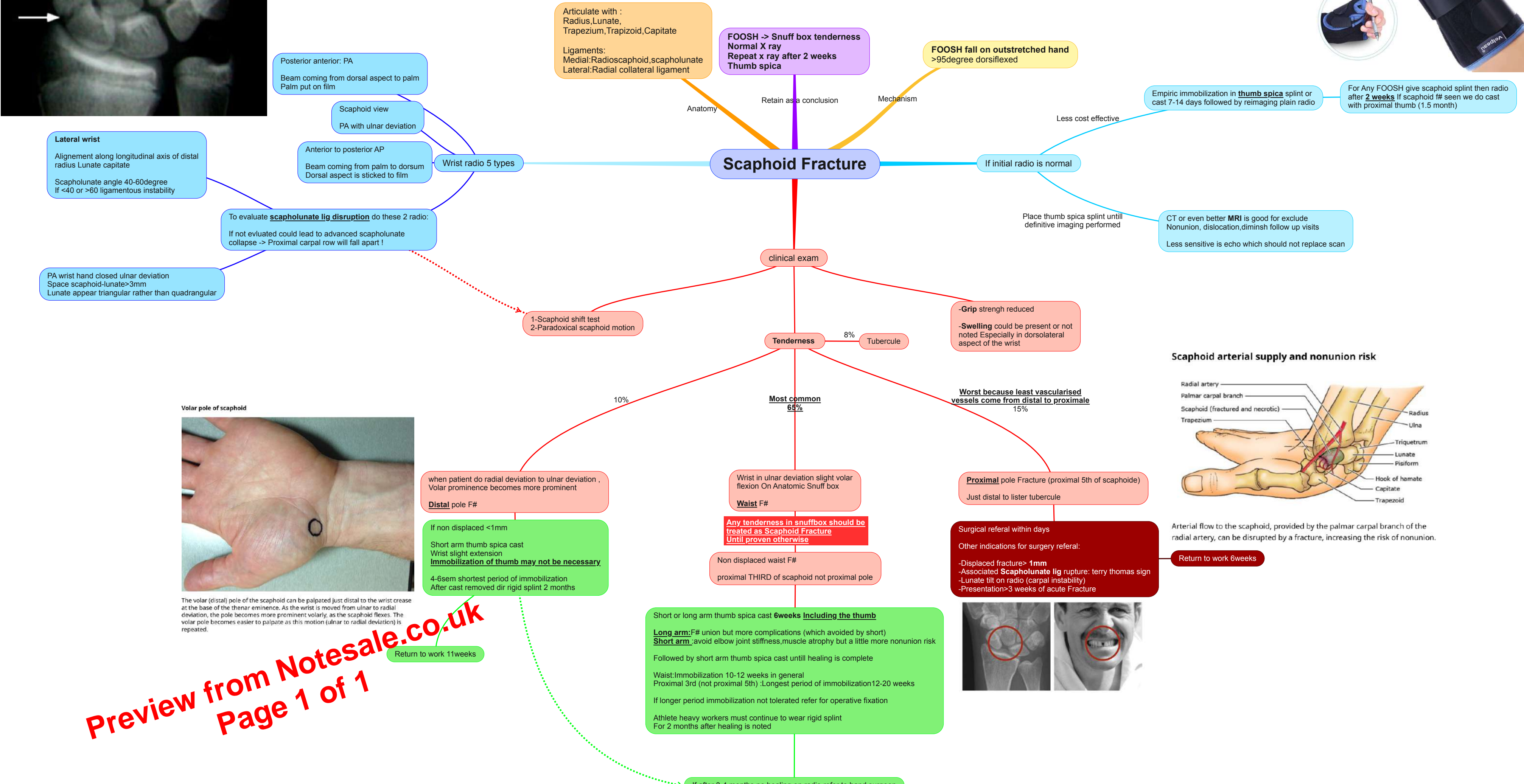
A precise anatomical description of the exact location of the fracture aids in localizing the fracture. The anatomical sites of scaphoid fracture are the tubercle, waist, proximal pole, and distal pole.



For Any FOOSH give scaphoid splint then radio after 2 weeks. If scaphoid fr seen we do cast with proximal thumb (1.5 month)

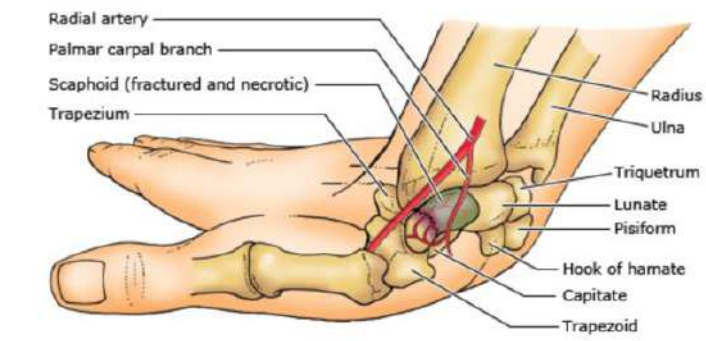


Scaphoid Fracture



The volar (distal) pole of the scaphoid can be palpated just distal to the wrist crease at the base of the thenar eminence. As the wrist is moved from ulnar to radial deviation, the pole becomes more prominent volarly, as the scaphoid flexes. The volar pole becomes easier to palpate as this motion (ulnar to radial deviation) is repeated.

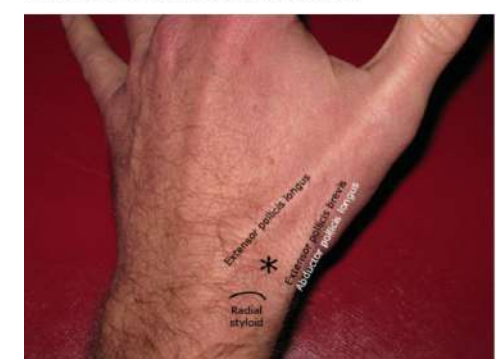Scaphoid arterial supply and nonunion risk



Arterial flow to the scaphoid, provided by the palmar carpal branch of the radial artery, can be disrupted by a fracture, increasing the risk of nonunion.

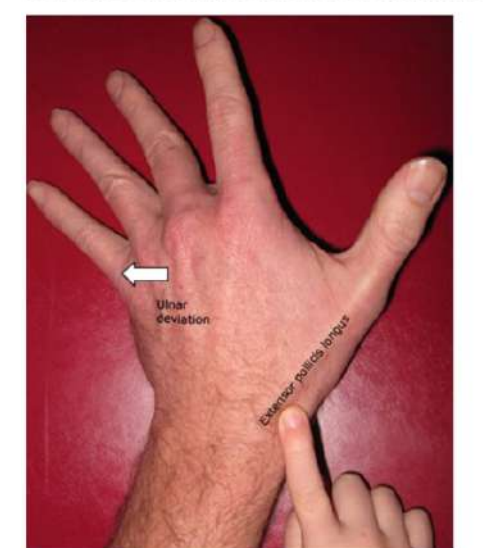Preview from Notesale.co.uk
Page 1 of 1

Location of the wrist anatomic snuffbox



The anatomic snuffbox is located proximal to the base of the thumb between the extensor pollicis longus tendon medially and extensor pollicis brevis and abductor pollicis longus tendons laterally. A fracture of the scaphoid waist often manifests as tenderness in this region.

Palpation of the scaphoid in anatomic snuffbox



A good method for evaluating the body of the scaphoid is to gently bring the patient's wrist into ulnar deviation and slight volar flexion, and then, palpate the anatomic snuffbox. The snuffbox lies between the extensor pollicis longus tendon medially and extensor pollicis brevis and abductor pollicis longus tendons laterally.