

Traumatic Injury to the Chest and Abdominal Viscera

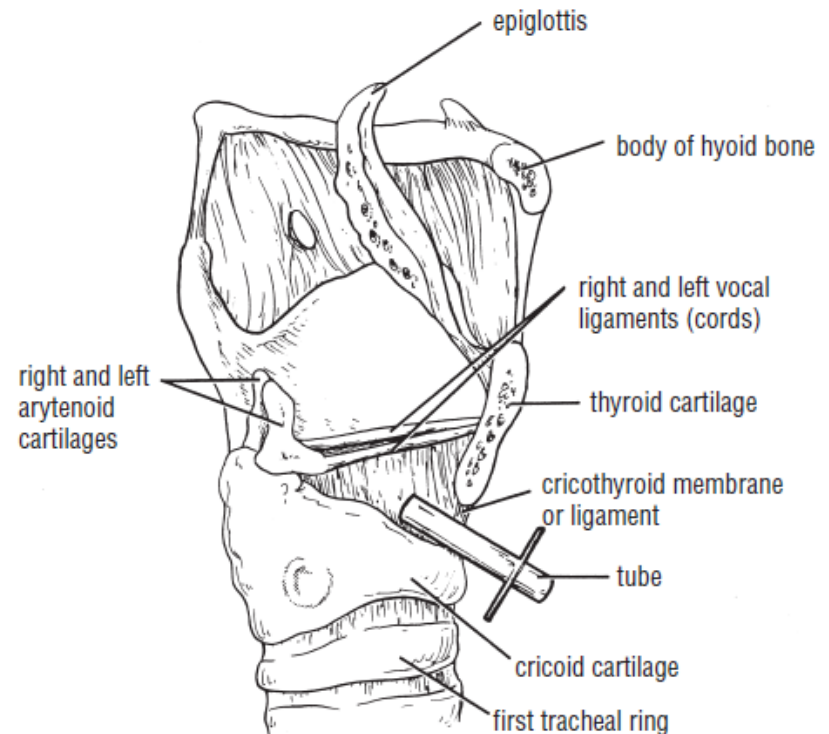
- The upper abdominal organs—namely, the liver, stomach, and spleen—may be injured by trauma to the rib cage.
- Any injury to the chest below the level of the nipple line may involve abdominal organs as well as chest organs.
- **Injury to the Back of the Chest:** The posterior wall of the chest in the midline is formed by the vertebral column. In severe posterior chest injuries, the
- possibility of a vertebral fracture with associated injury to the spinal cord.

Palpation of the Trachea

- The trachea can be readily felt below the larynx.
- It descends and becomes deeply placed about (4 cm) from the surface at the suprasternal notch.
- In the adult it measure about (2.5 cm) in diameter, but in a 3-year-old child it may only 1.25 cm. in diameter.
- The trachea is easily displaced by the enlargement of adjacent organs or the presence of tumours.
- lateral displacement of the cervical part of the trachea may be caused by a pathologic lesion in the thorax

Compromised Airway

- **Cricothyroidotomy.** In cricothyroidotomy, a tube is inserted in the interval between the cricoid cartilage and the thyroid cartilage.
- The trachea and larynx are steadied by extending the neck over a sandbag

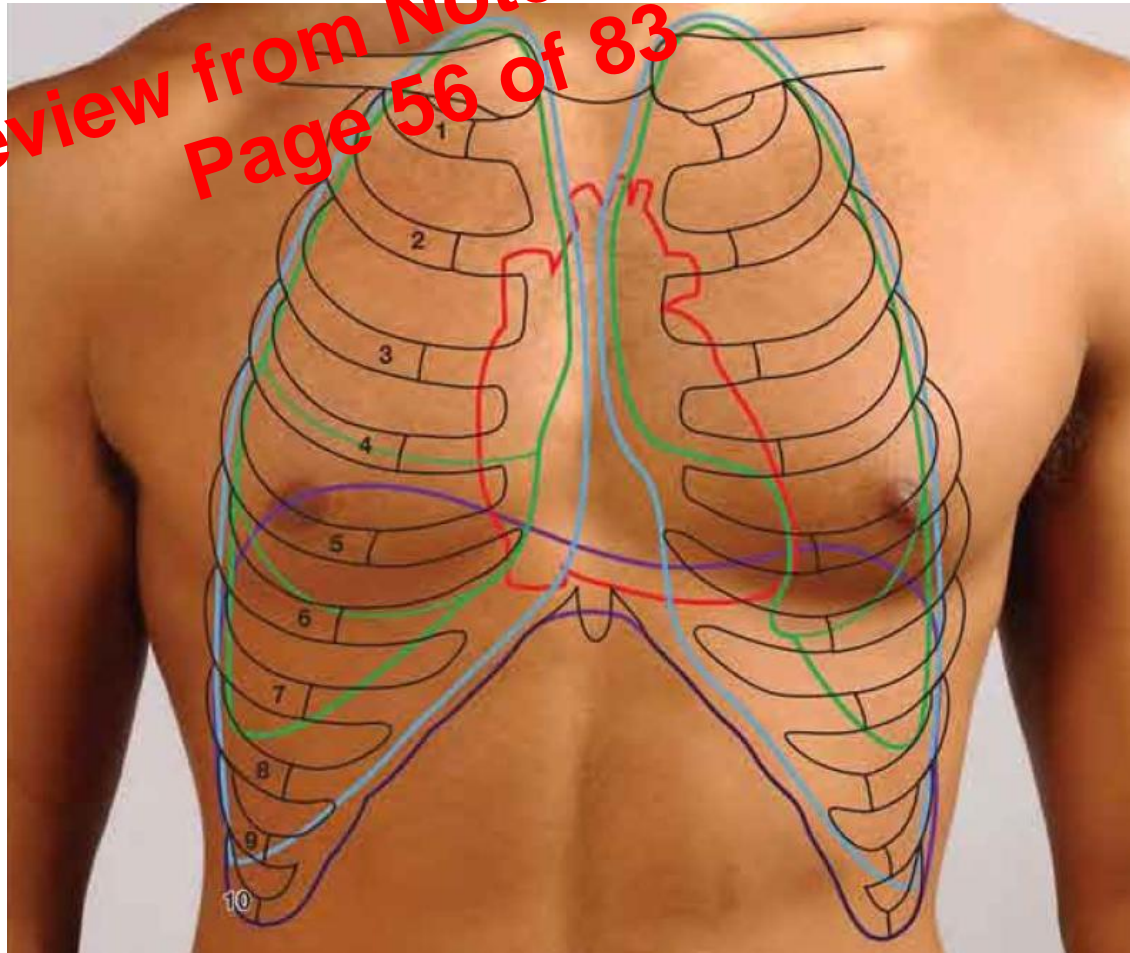


Complications

- Most complications result from not adequately palpating and recognizing the thyroid, cricoid, and tracheal cartilages and not confining the incision strictly to the midline.
- **Haemorrhage**: From the anterior jugular veins and the anastomosing branches of the superior and inferior thyroid arteries that cross the midline on the isthmus.

PLEURAL REFLECTION

Preview from Notesale.co.uk
Page 56 of 83



Thoracocentesis

- Fluid can be drained from the pleural cavity by inserting a wide-bore needle through an intercostal space (usually the 7th posteriorly). The needle is passed along the superior border of the lower rib.
- Below the 7th intercostal space there is danger of penetrating the diaphragm.

Needle Thoracostomy

- Two ways: Lateral and anterior Approach
- lateral approach, the patient is lying on the lateral side.
- The second intercostal space is used through the anterior axillary line.

Preview from Notesale.co.uk
Page 60 of 83

Anterior Approach

- For the anterior approach, the patient is in the supine position. The sternal angle is identified, and then the second costal cartilage, the second rib, and the second intercostal space are found in the midclavicular line.

Tube Thoracostomy

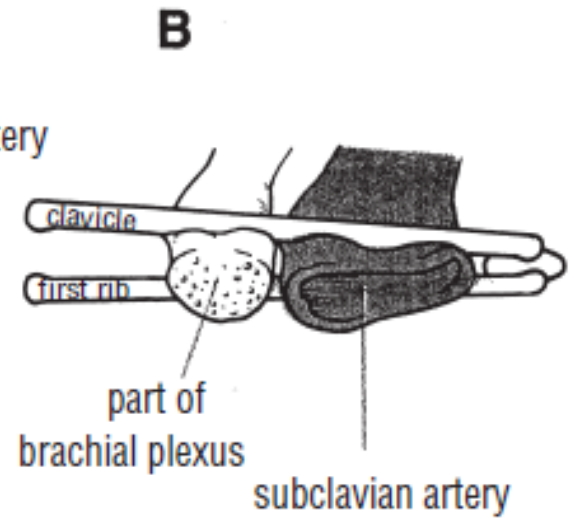
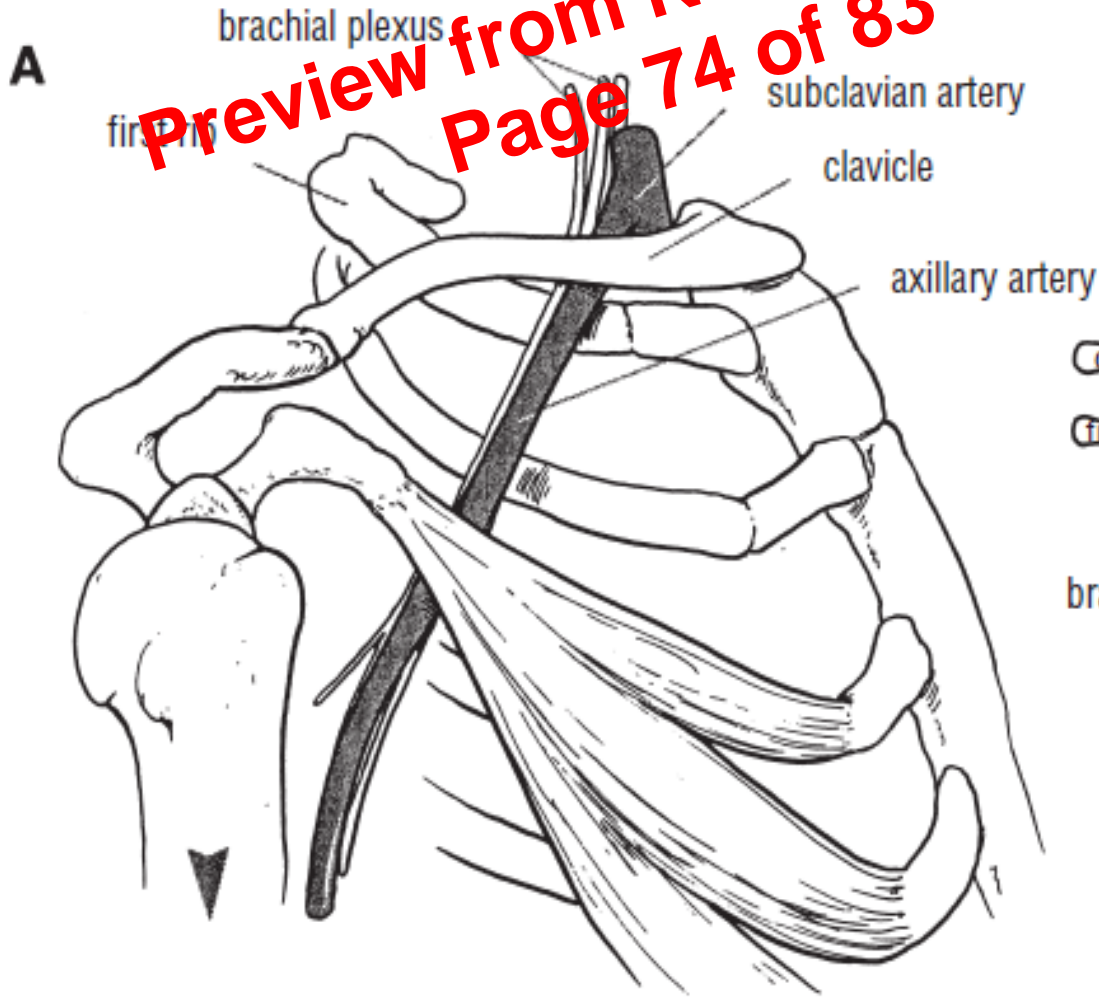
- The preferred insertion site for a tube thoracostomy is the fourth or fifth intercostal space at the anterior axillary line.
- The tube is introduced through a small incision.
- Note: Avoid damaging the diaphragm and entering the peritoneal cavity and injuring the liver, spleen or stomach.

The bronchopulmonary segments

- Each bronchopulmonary segment is pyramidal in shape with its apex directed towards the hilum.
- It is a structural unit of a lobe that has its own segmental bronchus, artery and lymphatics.
- The veins draining each segment are intersegmental
- If one bronchopulmonary segment is diseased it may be resected with preservation of the rest of the lobe..

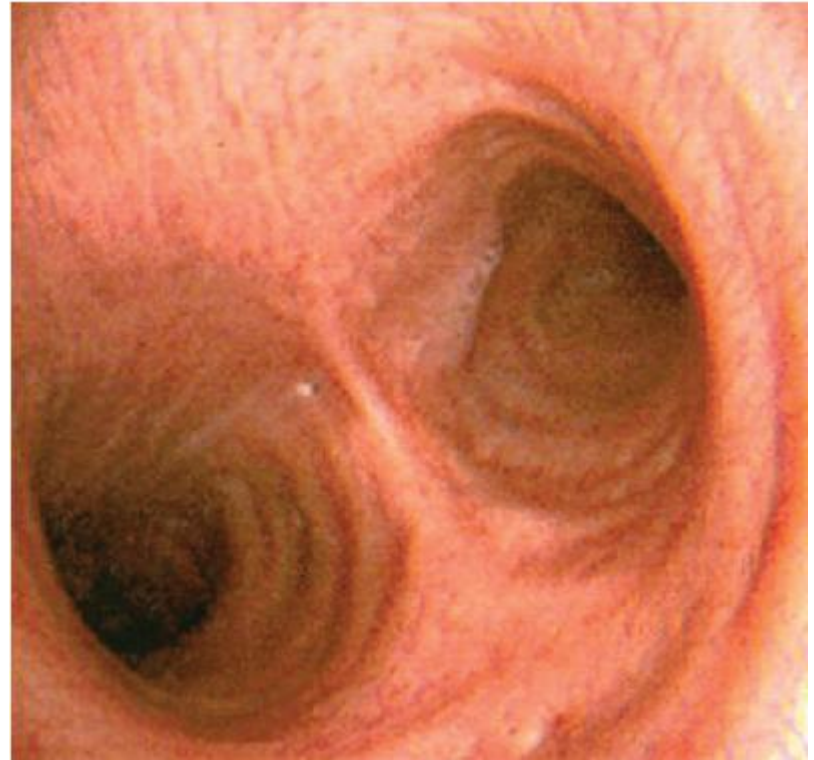The Thoracic Outlet Syndromes

Preview from Notesale.co.uk
Page 74 of 83



Bronchoscopy

- When examining the bronchi with a bronchoscope an endoscope one can observe a ridge, the carina, between the orifices of the main bronchi.



preview from Notesale.co.uk
page 79 of 83

Clinical Examination of the Chest

- *Palpation* enables the physician to confirm the impressions gained by inspection, especially of the respiratory movements of the chest wall. Abnormal protuberances or recession of part of the chest wall is noted. Abnormal pulsations are felt and tender areas detected.