

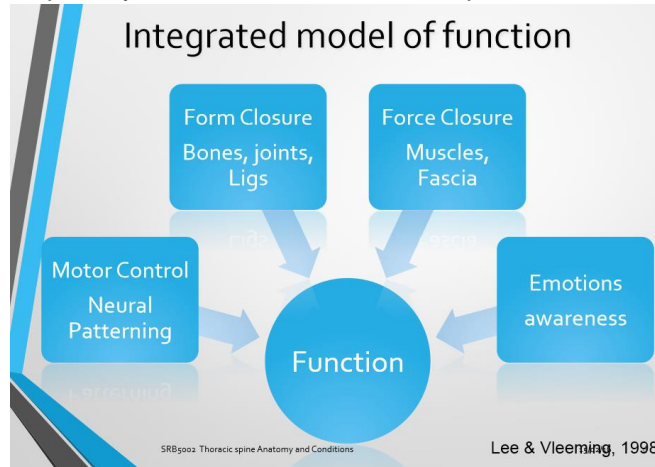
## Functions of the Thoracic Spine

### Load Transfer

• The rib cage provides passive stability due to multiple articulations at each level and needs the myofascial system for control.

### Balance of Mobility and Stability

• Balance and stability is modulated by the demand of a task – load, treat value without compressing respiratory function or intra-abdominal pressure.



### Use of the integrated model

- Local treatments can temporarily address painful structures
- Through considering the 4 components we can understand load transfer failure resulting in a concentration of forces rather than load sharing amongst structures
- E.g. lumbopelvic pain may result in unilateral muscle activation creates a rotation and side bending in Thx spine is painful.
- Pain-free lack of Thx movement may result in Cx or Lx pain due to compensation
- Dysfunctions of scapular stability may have a causative effect on the Thoracic spine

### Form Closure Anatomy

Cervical to Thoracic Vertebra

- 12 thoracic vertebrae
- Distinctive heart-shaped body; greater mass than Cx
- Vertebral foramen relatively small
- Long slender spinous processes project in posterior & inferior direction → N.B. for locating transverse process.
- Transverse process of each vertebra at level with Spinous Process of vertebra above. T11 & T12 may vary

Spinal Curvatures

- T7 is thought to be where the lower limb axial rotation alternates with the upper limb axial rotation. Due to weight bearing through Thx & Lx vertebra it is difficult to stabilise between Tx and Lx curvatures

Cervical to Thoracic Vertebra

- Each Thoracic vertebra articulates with ribs along the dorsolateral surface of the body

### 5 joints of thorax

1. Intervertebral Joints
2. Zygapophyseal/facet joint
3. Costovertebral joint
4. Costotransverse joint
5. Costochondral joint

### Intervertebral Joints

- Intervertebral discs relatively thin
- Along with presence of ribs results in reduced movement at IV joints
- Supported by ligaments;
- Anterior and posterior longitudinal ligament, supraspinous, interspinous intertransverse and ligamentum flavum with more support costovertebral joints and ligaments

### The zygapophyseal Joints – facets

- Upper Thoracic facet (T1-T6) lie in the frontal plane
- Facilitates Rotation coupled with side flexion
- Flexion and extension relatively limited in this area
- Lower Thoracic facet (T9-T12) more in the sagittal plane allowing increased flexion and extension
- Lack of shearing in Thx spine
- Dramatic change in orientation between T12&L1 – T12 more susceptible to #

### Costovertebral Joint

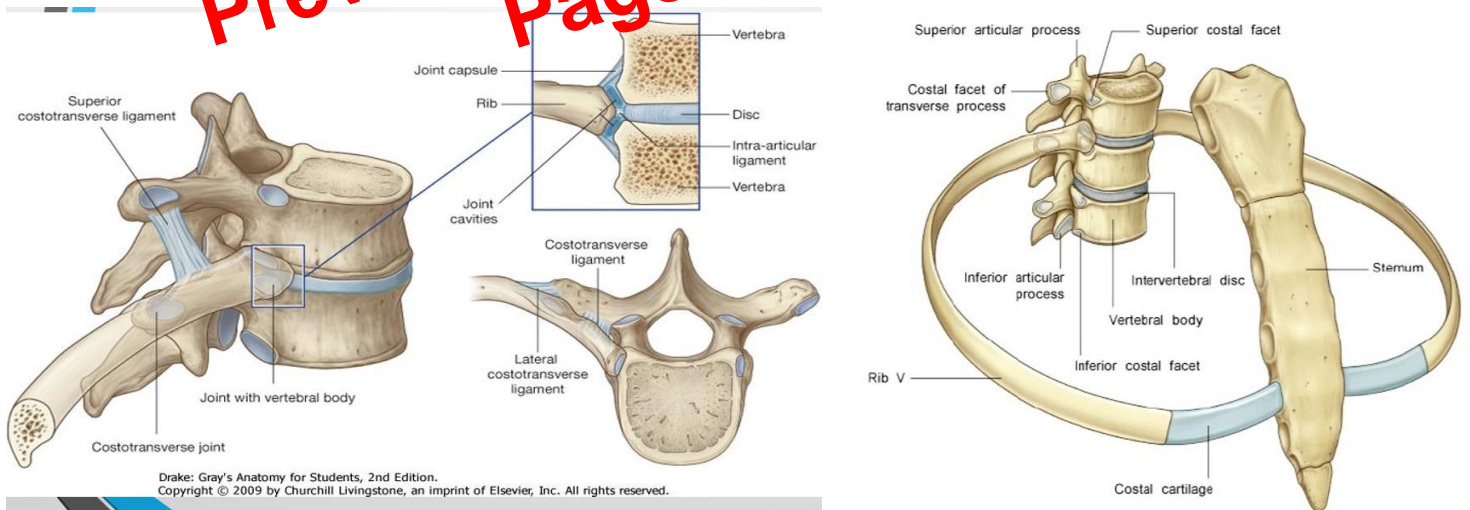
- Synovial Plane joints
- 12x2=24 joints - The location and structure of the articulation varies
- First rib originates at the body of T1 and has a whole facet and an inferior demifacet
- Ribs 2 - 8; originate between adjacent Vertebrae → T2-T8 have superior and inferior demifacets on each side
- T9 has only a superior demifacet
- T10, T11 and T12 have a single whole facet on each side

### Costotransverse joint

- T1-T10 have Costal facets on their transverse processes – articulation with tubercles of ribs
- Articular capsule (fibrous) surrounds each joint and is strongest anteriorly
- 11th and 12th rib do not have these
- Fibrous capsule is supported by 3 ligaments
- Superior Costotransverse
- Costotransverse ligament
- Lateral costotransverse ligament

### Costochondral Joints

- Between ribs and costal cartilage
- Joint between costal cartilage and sternum or 'costosternal joints'
- Ribs 8-10 join directly with the costal cartilage of the rib above; - 'false ribs'
- Ribs 11&12 don't attach to either cartilage or sternum - 'floating ribs'



### Movement of the Ribs during breathing/During Inspiration

- Ribs are pulled up & forward
  - Increases anteroposterior & transverse diameter of the ribs Different mechanisms
1. Pump handle – upper T1-T6
  2. Bucket Handle – Middle T7-T10

# Lumbar

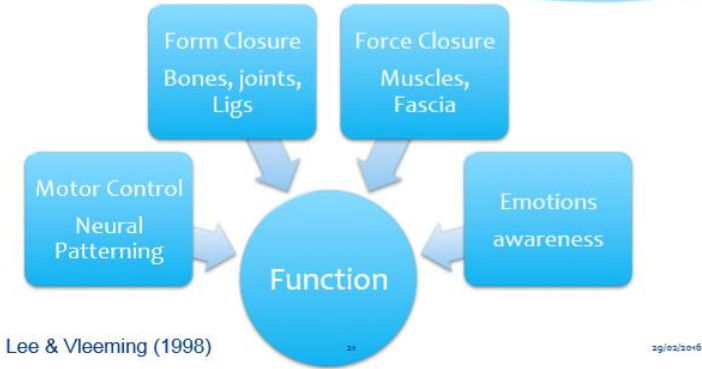
Preview from [Notesale.co.uk](http://Notesale.co.uk)  
Page 17 of 54

# Spine

# Sacroiliac Joint (SIJ)

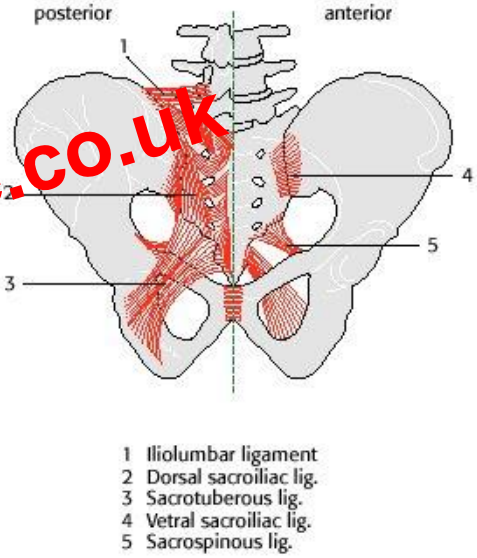
Preview from [Notesale.co.uk](http://Notesale.co.uk)  
Page 22 of 54

# Integrated model of function



**Stability and Form Closure**  
 Passive components of stability  
 Structures passively limit ROM  
 Serve to increase the friction coefficient and effectiveness of the compressive forces in limiting shear  
 The ligamentous complex contributes to the stability in a unique way; most ligaments tighten and slacken at the same time  
 Nutation causes tightening of the ligaments and counternutation causes it to relax  
 As sacrotuberous lig tightens – ilium and sacrum are drawn together – increasing friction between 2 bones – self locking – **functional tension dynamics**

**Ligaments of the SIJ**  
 Short posterior/dorsal SI lig – strongest, between lateral sacral crest and iliac tuberosity, prevents palpation of SI joint  
 Sacrotuberous lig – **resists nutation**  
 Dorsal/long dorsal posterior SI lig – tensed when legs are apart – **resists counternutation**  
 Sacrospinous lig – attaches from lower lateral aspect of sacrum and coccyx to ischial spine of innominate. Blends with capsule. Restores sacrum to resting position as pelvis returns to neutral mid stance



**Force closure**  
 Local stabilisers (pelvic floor, TVA, diaphragm and deep fibres of multifidus)  
 Function – stabilise the spine and pelvic girdle in preparation for additional external loads which is achieved through

- Inc intra-abdominal pressure
- Inc tension of the thoracodorsal fascia
- Inc articular stiffness

When CNS can predict the load, local system will anticipate the load

**Muscles**  
 Gluteus Maximus  
 Gluteus Minimus  
 Gluteus Medius  
 Piriformis  
 Tensor Fascia Lata

**Global Muscle system**  
 Contracting muscles produce forces that are transmitted tendons, ligs, muscles, capsules, bones and other muscles. Produces slings of force that assist in the transfer of load. Areas of weakness or tightness must be addressed.

### Somatic Pain

- First or 'fast' pain
- Protective event that enables the organism to localize pain rapidly and accurately and withdraw from the stimulus
- Produced by high threshold thermo/mechanical nociceptors, transmit action potential by fast conducting myelinated A $\delta$  fibres
- Conduction continues along second and tertiary afferent fibres to the cortex of the brain
- Short duration and does not cause tissue damage; pain disappears when stimulus stops

### Pathophysiological Pain

- Second or 'slow' pain
- Following tissue damage; surgery/ trauma/ inflammation
- Encourages tissue healing eliciting behavior to protect the damaged area
- Stimulation of nociceptors that respond to mechanical, chemical and thermal stimuli, transmitted by slow conducting unmyelinated C fibres
- Second order neurons to the midbrain, periaqueductal grey matter and hypothalamus
- Involved in producing the emotional and behavioural response to pain. N.b. in chronic pain

### Neuropathic Pain

- Injury to nerve fibers can lead to abnormal functioning of the nervous system
- Complete destruction/ transection – complete loss of muscle power and sensation
- Partial damage; due to crush injury/surgery or medical conditions (diabetes/shingles) can lead to altered sensation – altered temperature sensation/unusual or unpleasant feelings or pain

### Neuropathic pain – radicular pain

- Pain evoked by ectopic discharges emanating from the dorsal root or its ganglion
- Disc herniation is the most common cause
- Pain is 'lancinating' / shocking / electric type and travels the length of the limb
- Is relatively uncommon when precisely defined; prevalence is only 12% or less (Deyo, 1987)
- Neurological state in which conduction is blocked along spinal nerve or its root
- If sensory fibers then – Numbness
- If motor fibers then – weakness
- Diminished reflexes occur as a result of sensory/motor
- Radiculopathy and radicular pain commonly occur together, radiculopathy may occur without pain & radicular pain can occur without radiculopathy

### Somatic referred pain

- Does not involve stimulation of the nerve roots
- Produced by stimulation of nerve endings within the spinal structure, eg discs, zygapophyseal / SI joints
- Convergence of nociceptive afferents on second-order neurons in the spinal cord that happen to also supply regions in the lower limb- share the same segmental innervation at the source
- Dull, aching and gnawing /described as an expanding pressure

# Red Flags

Preview from [Notesale.co.uk](https://www.notesale.co.uk)  
Page 30 of 54

### Rx Effects

- Sliders
- Venous return, odema dispersal, ↓ pressure inside perineurium, ↑ circulation, ↑ axonal transport, ↑ O<sub>2</sub>, ↑ confidence, facilitates normal motor performance with pain free ROM (Coppieters & alshami, 2007)

### Precautions

- Care when pain production referring in to distal segment
- All spasm is respected and never forced movement
- Tethering of NS – repeated movements = ↑ symptoms
- Upper motor neuron signs

### Progression of Rx and Grades

- Start out of tension, gradual ↑
- Technique well removed from symptom area
- Non symptom provoking initially
- Best to under treat initially, until irritability related to Rx is established
- Grades
- Large amplitude grade II's slowly and rhythmically through range
- IV just up to resistance
- Largest amplitude of movement to be done
- Symptoms – respected and monitored at all times!

### 6. Monitoring

- Constant verbal / non verbal
- Dull constant ache avoided
- If symptoms reproduced – should be in rhythm with technique
- Client must be relaxed and comfortable
- Time – positioned in pain relieving position

### Responses to Rx

- Possible to change symptoms at time of Rx or hours later
- Problem is deemed less irritable passive movement – gentle manner may be applied to the symptom area

Preview from [Notesale.co.uk](http://Notesale.co.uk)  
Page 41 of 54

- Thx or Lx - Tingling in both lower limbs
- +ve Plantar response

### Contraindications to manipulation

#### Disorders

- spinal deformities i.e. spondylolisthesis/lysis
- suspicion of a disc herniation
- acquired hypermobility or instability
- neoplastic disease of musculoskeletal tissue
- bone disease – osteoporosis, osteomyelitis
- inflammatory arthritis – ankylosing spondylitis
- advanced degenerative changes
- central nervous disorders : cord signs cauda equina lesions – bladder/bowel dysfunction/saddle anaesthesia/paraesthesia
- 4
- cervical/thoracic conditions causing neurological deficits in upper and lower limbs
- severe nerve root pain – advanced diabetes and other metabolic disorders
- haemophilia - dizziness and vertebrobasilar insufficiency - vascular disorders – undiagnosed pain/visceral pain
- steroid or anticoagulation medication
- pregnancy – last two months
- recent whiplash - psychologically unsuitable

### Contraindications to manipulation

#### Clinical considerations –

- where features do not fit symptoms and signs do not match
- high irritability
- acquired instability or hypermobility of segment involved
- protective muscle spasm - rubbery end feel inability of patient to relax

### Indications for manipulation

To increase the range of movement in a vertebral joint or region of the spine:

- following a course of mobilisation when the range of progress is inadequate with regard to range of movement
- when a non-irritable pain is due to loss of range of movement and mobilisations have not relieved the symptoms
- when mobilisations are aggravating a non-irritable condition
- when an irritable joint disorder may be better treated by a single gentle manipulative thrust than repeated mobilisation
- when a “locked” facet joint is suspected

### Evidence for the effect of manipulation

- Manipulation induced hypoalgesia (pain relief) well documented
- Restoration of functional movement may reduce pain
- Pain-gate mechanism – stimulation of mechanoreceptors
- Stimulation of the descending inhibitory control pathways – endogenous analgesia (Wright, 1995)
- Increased cortical response
- Placebo effect (Ernst, 2000)
- Modified reflex motor response – changes in muscle tone